

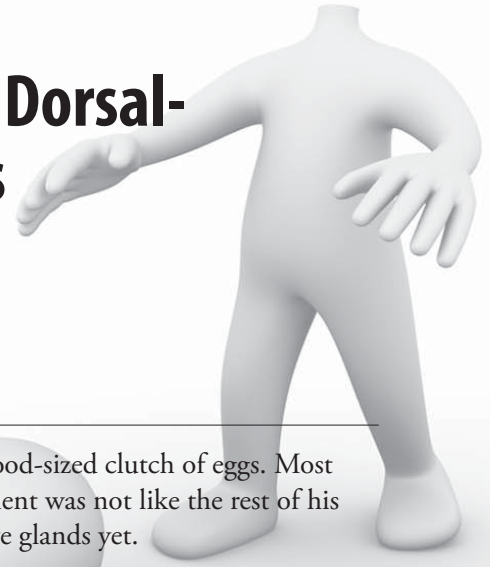
Don't Lose Your Head! A Case Study in Dorsal-Ventral Axis Formation in Amphibians

by

Debra A. Meuler

Biology Department

Cardinal Stritch University, Milwaukee, WI



John and Heather Pipiens were very nervous. Heather had recently given birth to a good-sized clutch of eggs. Most of the little larvae were doing fine. The one exception was Barney. His head development was not like the rest of his siblings. His head seemed smaller than it should be, and he hadn't formed his adhesive glands yet.

"What do you think could be wrong?" asked Heather, who looked very worried.

"Don't get all worked up," replied John. "I am sure it's nothing. He just may be a little slower than the rest of the kids. We have 133 perfectly normal, healthy little larvae and not all of them developed at the exact same rate. Remember Gracie? She gastrulated almost a day later than the rest and she's just fine. And Jason didn't have his first cleavage until almost an hour after the others, and he's doing great."

Just then the nurse came out and called their name. They were escorted into an examination room. Barney's height, weight, and somite count were taken. The nurse then told them that Dr. Triturus would see them in a few minutes.

True to her word, the doctor came into the exam room five minutes later. He took one look at Barney and his heart sank. He knew something was very wrong. He was definitely missing part of his forebrain and his entire adhesive gland. Based on his somite count, both should be very well developed by now.

Dr. Triturus turned and looked at the Pipiens and said, "Mr. and Mrs. Pipiens, at first glance there seems to be a problem with his developmental progress. He does have some head development abnormalities that I don't believe are related to timing. Everything else seems to be okay; he has the correct number of somites for his age and his trunk seems to be developing just fine. The problem seems to be the front-most part of his head. It has failed to develop. I don't know the exact cause just yet. I would like to admit him for some tests."

"Is that really necessary?" asked Barney's mom. "How serious is it? Can it be fixed?"

"I really can't say at this time," replied Dr. Triturus. "I need to do some tests to get a better idea of what is causing Barney's problem before I can make a diagnosis. I would like you to leave him here over the weekend. You can pick him up on Monday."

"But we want to stay with him," said both his mom and dad.

"That really isn't necessary. He is still in his jelly coat and not really aware of what is going on. Besides, you have 133 other children to take care of. Go home. He'll be in good hands with us."

John and Heather kissed Barney good-bye. The doctor had the nurse admit him and get him settled into his hospital tank. He then called his students together. Dr. Triturus had a pretty good idea of the cause of Barney's problems, but wanted to give his residents a chance at the diagnosis before he ran tests to confirm his hypothesis.

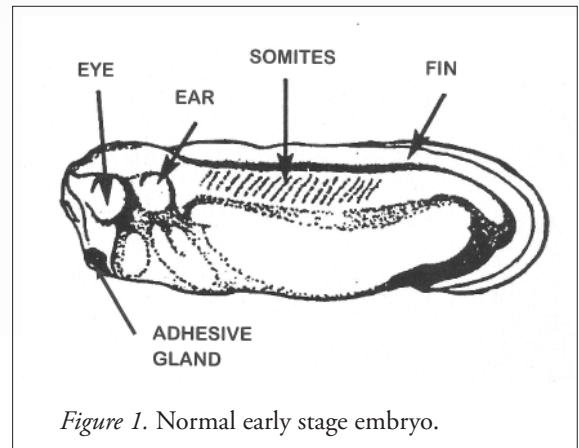


Figure 1. Normal early stage embryo.

Dr. Triturus began, “We have a 4-day-old male anuran with abnormal head development. He is showing an absence of forebrain development and his adhesive glands have failed to form. Everything else seems to be normal. What are your thoughts?”

The med students looked at one other. Robert thought it might be a problem with his Nieuwkoop center. Sarah thought it was probably a problem with his organizer. Karen told them that they both were wrong and it had to be a problem that occurred during neurulation. It was obvious that this group of students had no real idea of what was going on.

“You are on track, just not the right one. It’s a problem with dorsal-ventral axis formation. But it’s obvious that most of you don’t know much about the development of the central nervous system. Go home and do some research on this and be prepared to answer some questions during rounds tomorrow afternoon. I am disappointed about how little you seem to know about this subject. It is one of the first developmental decisions an embryo makes and one of its most important. Go do some research and be prepared to have better answers tomorrow.”

Dr. Triturus went over to Barney’s tank to check on him one more time. Satisfied that he would be all right until morning, Dr. Triturus went home hopeful that his students would be better prepared the next time they met. If not, some of them might find themselves cleaning tanks for the next two weeks.

You are part of Dr. Triturus’s research group. You really don’t want to clean hospital tanks for the rest of your residency. To prepare for tomorrow’s rounds, answer the following questions and be ready to provide a diagnosis of the cause of Barney’s head abnormalities. Be prepared to justify your reasoning.

Questions

1. What are the organizer and the Nieuwkoop center mentioned by Robert and Sarah?
2. Dr. Triturus indicated that Barney’s problem had something to do with dorsal-ventral axis formation. Establishment of the DV axis in amphibians is an example of conditional specification. In this type of development, a cell’s fate is determined by interactions between neighboring cells referred to as induction. What inductive events occur during DV axis formation in amphibians?
3. Research DV axis formation in amphibians and answer the following questions:
 - a. How is the Nieuwkoop center formed?
 - b. How is the organizer formed?
 - c. What causes neural induction?
4. Create a flow chart/concept map showing the relationship between the following for development and activity of the Nieuwkoop center.

a. Disheveled	b. β -catenin	c. Wnt11	d. Vegetal cortex
e. GSK-3	f. Twin	g. TCF3	h. Cortical rotations
i. Siamois	j. Sperm entry point	k. GBP	
5. How is the regional specification of mesoderm determined using β -catenin, VegT, Vg1, and Xnr?
6. Create a flow chart/concept map showing the relationship between the following for development and activity of the organizer.

a. Siamois	b. BMP	c. Noggin	d. Chordin
e. Dickkopf	f. Frzb	g. Wnt 8	h. Cerberus
i. Goosecoid	j. Follistatin		
7. Robert thought Barney’s problem resided in his Nieuwkoop center. What do you think?

8. Sarah thought it was a problem with his organizer. Do you agree or disagree?
9. Karen believed it was a problem with neurulation. Is this the reason?
10. What do you think is causing Barney's problem? Do you think he can be "cured"?
11. Explain the following observations:
 - a. Transplantation of a second dorsal lip to the ventral marginal zone of an embryo causes the embryo to develop a second axis, resulting in a second embryo joined to the host.
 - b. Injection of excess β -catenin into the ventral side of an oocyte causes a secondary axis to form.
 - c. UV irradiation of the vegetal hemisphere of an oocyte prevents cortical rotations after fertilization and no DV axis formation.
 - d. Animal caps dissected from blastula differentiate into ectoderm, but the same animal caps combined with vegetal fragments from a blastula stage embryo causes mesoderm differentiation.
 - e. Goosecoid RNA injected into the two ventral blastomeres causes a secondary axis to form.
 - f. Injection of noggin mRNA into 1-celled UV irradiated embryos rescues the UV phenotype and embryos develop normally.
 - g. Injection of cerberus mRNA into the vegetal ventral blastomere of a 32-celled embryo causes a second head to form.
12. Predict the consequences of each of the following, justify your reasoning, and provide a description or drawing of how the embryo would look with each mutation or change.
 - a. Experimental depletion of β -catenin using anti-sense RNA injected into an oocyte.
 - b. A TCF3 mutation where TCF3 is missing its β -catenin binding domain.
 - c. Knock out chordin gene expression using morpholino antisense oligomers.
 - d. Inject antibodies to dickkopf into embryos.
 - e. Knock out GSK-3 function using a dominant inactive GSK3 injected into both blastomeres of a 2-celled embryo.
 - f. Injection of siamois into the ventral vegetal cells.

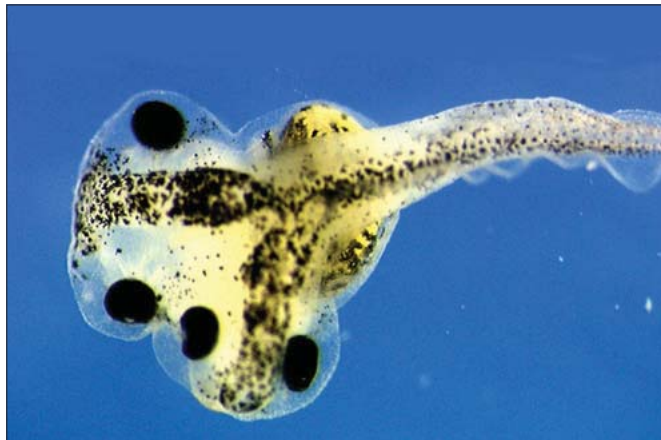

Figure 2. Xenopus embryo with two heads after experimental stimulation of the head inducer Dickkopf1.



Licensed illustration in title block © Air0ne - Fotolia.com, ID #27764297. Figure 1 courtesy of Nasco. Figure 2 courtesy of Christof Niehrs, Molecular Embryology, Cancer Research Center, Heidelberg, Germany. Case copyright held by the **National Center for Case Study Teaching in Science**, University at Buffalo, State University of New York. Originally published May 17, 2013. Please see our [usage guidelines](#), which outline our policy concerning permissible reproduction of this work.